

Platelet Rich Plasma Prolotherapy For Rotator Cuff Tears

Physicians should consider platelet rich plasma prolotherapy for patients with tendinopathies or rotator cuff tears before any surgical interventions.



History: A 40-year-old woman presents with a 3-year history of right shoulder pain, which began during a kickboxing workout. She “pushed past the pain” on three subsequent workouts until she could no longer lift her arm or continue her work as a hairdresser. She saw three orthopedic surgeons with various diagnoses including lax capsule secondary to repetitive use, repetitive strain, thoracic outlet syndrome, and “nothing wrong.” She received a cortisone shot, which was “a miracle.” However, a second injection was ineffective in relieving her pain, which had returned more severely than before. She tried acupuncture for a year and a half without improvement and then began physical therapy, which aggravated the problem. Ibuprofen 800 mg three times daily temporarily helped and she had been taking this medication continually over the last 2 years. She describes her pain as “24/7” with “shooting pains” across the joint, which felt “hot” but otherwise was mostly a constant dull ache. She was unable to lie on her aggravated shoulder and frequently had disrupted sleep from pain. Her neck had begun to bother her recently, with muscle spasms especially on the right side, and her shoulder range of motion had decreased. Physical activity, especially related to her career as a hairdresser, aggravated her pain and she had been unable to work regularly for several months. She felt she had tried all other available conservative treatments and was fearful of being unable to continue her profession or participate in sports.

Donna D. Alderman, DO
Osteopathic Physician and Surgeon
Medical Director
Hemwall Center for Orthopedic
Regenerative Medicine
Valencia, California
Alameda, California

Sean C. Robbins, BA
Research Assistant
Hemwall Center for Orthopedic
Regenerative Medicine
Valencia, California

Rotator cuff tears are one of the most common causes of chronic shoulder pain and disability of the upper body.¹ This injury is common among athletes, but is not limited to that demographic. In fact, injuries can occur to virtually anyone during everyday activities or with chronic overuse.² Approximately 7.5 million visits are made to physicians’ offices per year for shoulder pain.³ Greater than 50% of these physician visits result in a diagnosis of rotator cuff tendinopathy, with supraspinatus partial thickness tendon tears and tendonosis being most common.⁴ Magnetic resonance imaging (MRI) alone as a diagnostic tool can be inaccurate or inconclusive⁵ and should never take the place of a good history and physical examination correlated to a patient’s pain. Musculoskeletal ultrasound has emerged as an effective noninvasive, cost-effective approach with an accuracy rate similar to MRI⁶ and the advantage of real-time dynamic

imaging, with immediate in-office correlation to a patient’s area of complaint.⁷

Nonoperative treatment has proven to be beneficial to a great majority of patients with rotator cuff partial thickness tears and/or tendinopathy.⁸ Surgery has risks such as infection, damage to surrounding nerves and blood vessels, and general anesthesia⁹ with recovery taking up to 6 months depending on the severity of the injury. Stiffness, weakness, chronic pain,⁹ or incomplete healing after surgery can occur.¹⁰ Nonoperative treatment is therefore attractive and has been shown to have a high success rate.¹¹ Platelet rich plasma (PRP) prolotherapy continues to increase in use in orthopedics, with the American Academy of Orthopaedic Surgeons summarizing that “available data suggest PRP may be valuable in enhancing soft-tissue repair and wound healing.”^{12,13} The use of ultrasound guidance for PRP injections is also increasing in use in the office setting. *Current Reviews in Musculoskeletal Medicine* states: “It is recommended to use

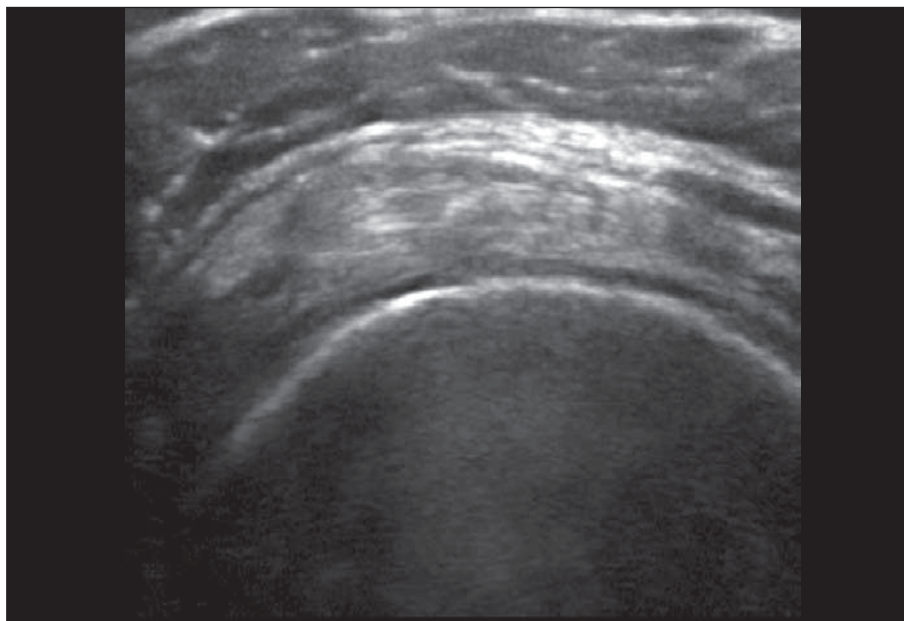


Figure 1. “Before” image of a supraspinatus tendon depicting an intrasubstance partial thickness tear and tendonosis.

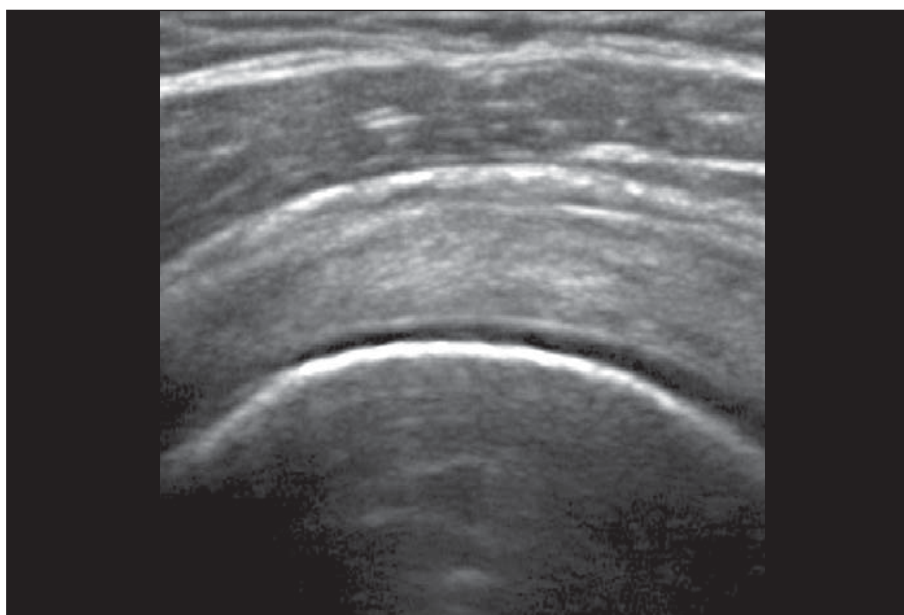


Figure 2. “After” image of a supraspinatus tendon demonstrating improvement in rotator cuff tendon tears and tendonosis.

dynamic musculoskeletal ultrasound ... in an effort to more accurately localize the PRP injection.”¹⁴

Evaluation

Examination of the patient revealed profound trapezius spasm on the right, with tenderness at the cervical-thoracic interspinous ligaments at C5

through T4. Right shoulder abduction was restricted to 120° with mild “stickiness” indicative of adhesions. There was a positive anterior compression test, with tenderness to palpation anteriorly. An MRI performed 2 years prior showed “mild hypertrophic disease of the acromioclavicular joint with some edema and a type 1

acromion with lateral downsloping but intact rotator cuff tendons with no evidence of tear or tendinopathy.” Musculoskeletal ultrasound performed in our office showed an intact bicep without deficit; however, there was a subscapularis tendon intrasubstance partial thickness tear and tendonosis, and supraspinatus articular surface partial thickness tear with calcific tendonosis at the enthesis. The acromioclavicular joint had a small effusion with degenerative changes but no anterior impingement noted. Glenohumeral joint was normal (Figure 1).

Diagnosis

We diagnosed the patient with partial thickness rotator cuff tears (subscapularis, supraspinatus) and diffuse tendonosis treated with PRP prolotherapy using ultrasound-guided injections. This patient also had early adhesive capsulitis (“frozen shoulder”) secondary to her chronic non-use, and compensatory cervicothoracic sprain/strain, which were also addressed during the treatment course.

Prolotherapy Treatment

This patient received a total of 6 PRP prolotherapy treatments over 9 months prepared using the SmartPREP II FDA-approved device (Harvest Technologies Corporation, Plymouth, Massachusetts). Ultrasound guidance using the M-Turbo ultrasound system (SonoSite, Inc., Bothell, Washington) was done to direct PRP injections into tendon defect sites. The patient also received a total of 5 dextrose prolotherapy treatments to the cervicothoracic spine (C5-T4). Because of the patient’s early adhesive capsulitis, aggressive osteopathic manipulative treatment (OMT) was done to break adhesions after first administering an intra-articular procaine injection to produce mild joint

anesthesia. OMT was given four times during the treatment course. The patient was also encouraged to “use” but “not abuse” her shoulder after treatments to discourage the return or increase in her secondary adhesive capsulitis.

Outcome

At the start of treatment, the patient indicated that pain was “24/7” and believed she would have to discontinue her profession. She had been unable to work when she was first evaluated. After the first treatment, the patient reported 10% improvement in the shoulder and 25% improvement in neck and trapezius pain. Treatment intervals were approximately 1 month apart. After the second treatment, the patient had an exacerbation of her pain and adhesive capsulitis. She received an osteopathic shoulder mobilization treatment, which freed adhesions and corrected her cervicothoracic somatic dysfunction. The patient experienced prolonged after-treatment pain with the third treatment, and her fourth treatment was postponed for 1 month. At that point, 5 months after treatment onset, the patient reported a 60% to 70% improvement in overall pain, function, and mobility. One month later on the fifth office visit, she indicated 80% improvement, and after the sixth treatment the patient said she felt 90% improvement and exclaimed, “I feel awesome!” and, “My improvement has been significant and obvious.” Physical examination was negative for anterior compression and range of motion was normal. Ultrasound evidence showed improvement of rotator cuff tendon tears and tendonosis (Figure 2). The patient returned to work full time, and follow up 6 months later showed continued improvement and stability.

Conclusion

Rotator cuff tears and dysfunction can be challenging for the primary care, orthopedic, pain, or sports medicine physician, especially where there is an overlay of secondary adhesive capsulitis or compensatory cervicothoracic sprain/strain. Our case report demonstrates the effective use of PRP prolotherapy injections to stimulate repair of partial thickness tears of rotator cuff tendons, with good results. Ultrasound guidance to ensure accurate placement is important when these specific deficits exist. PRP prolotherapy should be considered for rotator cuff tears or tendinopathies before operative intervention, especially where surgical necessity is unclear. ■

Authors' Bios: *Donna D. Alderman, DO, is a graduate of Western University of Health Sciences, College of Osteopathic Medicine of the Pacific, in Pomona, California, with an undergraduate degree in nutrition from Cornell University in Ithaca, New York. She attended the first Gustav A. Hemwall, MD, prolotherapy injection seminar in 1998 and has extensive training in prolotherapy and PRP prolotherapy. She teaches and is on the Board of Trustees of the American Osteopathic Association of Prolotherapy Regenerative Medicine and a member of the American Association of Orthopaedic Medicine. Dr. Alderman has published multiple journal articles on the subject of prolotherapy and in 2008, she authored the book, Free Yourself from Chronic Pain and Sports Injuries.*

Sean C. Robbins, BA, is a graduate of Boston College, where he earned his Bachelor of Arts degree. While earning his undergraduate degree, he was a member of the NCAA Division 1 Men's Swimming Team where he represented Boston College in interscholastic national competition. Mr. Robbins is currently a graduate student at Washington University in St. Louis, where he is a

member of the Post-Baccalaureate Pre-Medical Program, completing his medical school prerequisites.

Dr. Alderman and Mr. Robbins have no financial information to disclose.

References

1. Chakravarty K, Webley M. Shoulder joint movement and its relationship to disability in the elderly. *J Rheumatol.* 1993;20(8):1359-1361.
2. American Academy of Orthopaedic Surgeons. Common shoulder injuries. <http://orthoinfo.aaos.org/topic.cfm?topic=a00327>. Accessed August 14, 2012.
3. Centers for Disease Control and Prevention. National ambulatory medical care survey 1998-2006. <http://www.cdc.gov/nchs/ahcd.htm>. Accessed August 14, 2012.
4. Kim HM, Dahiya N, Teefey SA, et al. Location and initiation of degenerative rotator cuff tears. *J Bone Joint Surg Am.* 2010;92(5):1088-1096.
5. Schröder RJ, Bostanjoglo M, Käab M, et al. Accuracy of routine MRI in lesions of the supraspinatus tendon—comparison with surgical findings. *Rofo.* 2003;175(7):920-928.
6. de Jesus JO, Parker L, Frangos AJ, Nazarian LN. Accuracy of MRI, MR arthrography and ultrasound in the diagnosis of rotator cuff tears: a meta-analysis. *AJR Am J Roentgenol.* 2009;192(6):1701-1707.
7. Teefey SA, Hasan SA, Middleton WD, Patel M, Wright RW, Yamaguchi K. Ultrasonography of the rotator cuff. A comparison of ultrasonographic and arthroscopic findings in one hundred consecutive cases. *J Bone Joint Surg Am.* 2000;82(4):498-504.
8. Ciccotti MA, Ciccotti MC, Ciccotti MD. Rotator Cuff Injury. Ed. Cosgarea, AJ. *Hospital Physician: Orthopaedic Sports Medicine Board Review Manual.* Volume 2, Part 2. Turner White Publications, Inc: Wayne, PA; 2005:1-11.
9. American Academy of Orthopaedic Surgeons. Shoulder surgery. <http://orthoinfo.aaos.org/topic.cfm?topic=a00066>. Accessed August 14, 2012.
10. Medline Plus. Rotator cuff repair. <http://nlm.nih.gov/medlineplus/ency/article/007207.htm>. Updated June 30, 2011. Accessed August 14, 2012.
11. Kuhn JE. Rotator Cuff Injury. Ed. Bhandari M. *Evidence-Based Orthopedics.* Wiley-Blackwell: Oxford, UK; 2011:Chapter 88.
12. Murray MM, Spindler KP, Ballard P, Welch TP, Zurakowski D, Nanney LB. Enhanced histologic repair in a central wound in the anterior cruciate ligament with a collagen-platelet-rich plasma scaffold. *J Orthop Res.* 2007;25(8):1007-1017.
13. Boyan BD, Schwartz Z, Patterson TE, Muschler G. Clinical use of platelet-rich plasma in orthopaedics. *AAOS Now.* 2012;6(8). <http://www.aaos.org/news/bulletin/sep07/research2.asp>. Accessed August 14, 2012.
14. Sampson S, Gerhardt M, Mandelbaum B. Platelet rich plasma injection grafts for musculoskeletal injuries: a review. *Curr Rev Musculoskeletal Med.* 2008;1(3-4):165-174.