

# Comprehensive Scientific Overview on the Use of Platelet Rich Plasma Prolotherapy (PRPP)

Karina Gordin, BA, MS

## ABSTRACT

As noted in this review, over the past decade substantial advancements have been made in optimizing musculoskeletal diagnoses and repair. As a result, the research trend has evolved to recognize preventative measures and innovative treatments, which ultimately aim to improve patient quality of life and reduce the costly social impact of soft tissue and joint pathologies. One such treatment, which stands out for its cost-effectiveness and regenerative capabilities, is Platelet Rich Plasma Prolotherapy (PRPP). Now used with increased frequency for conditions such as tendinopathy, sprains, strains and laxities, PRPP is an effective alternative to conventional treatments (NSAIDs, surgery, corticosteroids) on account of its supra-physiologic concentration of platelets rich in the seven fundamental protein growth factors, which play a central role in the healing process.<sup>1</sup>

*Journal of Prolotherapy*. 2011;3(4):813-825.

KEYWORDS: autologous blood, cartilage, collagen, growth factors, inflammation, injection, musculoskeletal injuries, platelets, Prolotherapy, tendonitis.

## A NEW PARADIGM

As the 2000-2010 *Bone and Joint Decade* elapsed, its global initiative to advance research of joint injuries<sup>2</sup> ushered in therapeutic interventions that aimed to enhance tissue regeneration and reduce degenerative mechanisms. The current research trend in the arena of joint injury launched breakthroughs in scientific investigations and technology, providing important new insights into musculoskeletal injury, which, according to a study conducted by the World Health Organization, is the most frequent cause of intensive long-term pain and disability, affecting millions of people worldwide.<sup>3</sup> Musculoskeletal diseases, ranging from back pain and bodily injuries to arthritis and osteoporosis, are reported more often than any other health complaint by U.S. patients. In 2004, lost wages and treatment expenses related to musculoskeletal diseases was estimated to cost a total of \$849 billion, equal to 7.7% of the gross

domestic product (GDP).<sup>4</sup> In 2005, the majority of both lost work and bed days were attributed to health conditions associated with musculoskeletal diseases.<sup>5</sup> The social impact of bone and cartilage pathologies imposes high costs and ultimate loss of income: in the United States alone, osteoarthritic medicines cost \$5.31 billion in 2007,<sup>6</sup> and musculoskeletal conditions cost nearly \$128 billion per year in direct medical expenses.<sup>7</sup> Such as, one report approximated the total cost of bilateral knee joint replacements at over \$85,000, which included a hospital stay, surgeon and anesthesiologist fees, a 5-day inpatient rehabilitation center stay, and a pathologist visit.<sup>8</sup>

Without a doubt, the need to spotlight musculoskeletal conditions and functional, cost-effective treatments is urgent, considering factors such as increased popularity of sporting activities and related tissue injuries, including tendon and ligament trauma accounting for 45% of all musculoskeletal injuries in the U.S.A.<sup>9</sup> Broadly speaking, insufficient understanding of these escalating musculoskeletal disorders, including osteoarthritis development, has generated a wide array of symptom based treatment options, including narcotics, anti-inflammatories, corticosteroid injections, surgery, ice, heat, analgesics, rest, braces and wraps, and physical therapy.<sup>10</sup> Considering such protocols, it is apparent that basic human physiology is misapplied; namely, common tendon therapies aim at handicapping inflammation, while false assumptions attribute inflammation to osteoarthritis whereas the etiology primarily involves degeneration. In fact, the term *osteoarthritis*, relating to the most common form of arthritis, is a bit of a misnomer, and may be better identified as osteoarthrosis, since inflammation plays an insignificant role compared to corroding of cartilage and loss of sensory innervations of the joint and surrounding muscles. What initially starts off as a sprain or strain, commonly attributable to excessive forces applied to a joint in an abnormal direction, eventually translates into meniscal and ligamentous injury, ultimately leading

to increased instability within a joint.<sup>11</sup> Progression of such degeneration eventually indicates arthroscopy, joint replacement, or in some cases spinal fusion as last resort care when pain, disability and imaging studies warrant it. If imaging studies focused beyond common sources of pain like degenerative joint cartilage and spinal disc disability, and considered pain generators like ligaments, joint capsules, muscles and tendons, then would surgery still be warranted as the last resort? According to large randomized trials examining such interventions, it was concluded that surgery like arthroscopy has a limited role as a treatment of osteoarthritis.<sup>12</sup> The fact that soft tissues (connective tissues) and alternative interventions are rarely considered in diagnosis, avoidable and expensive protocols are performed, generating annual direct medical, drug and indirect work loss costs at \$8,601, \$2,941, and \$4,603, respectively.<sup>13</sup> Accordingly, reliable preventative interventions and regenerative solutions pose promising new alternatives to traditional long-term palliative care,<sup>14</sup> improving clinical outcomes, and providing a new perspective on understanding the wound healing process.

Amongst a variety of breakthroughs addressing musculoskeletal conditions, Platelet Rich Plasma Prolotherapy (PRPP) stands out as a minimally invasive procedure that both safely and effectively accelerates natural healing, prompting the sequellae of reduced treatments frequency and morbidity, while reinforcing functional recovery.<sup>15</sup> Since first being introduced by Ferrari et al.<sup>16</sup> in 1987 following an open heart surgery, platelet rich plasma has swiftly gained recognition as a versatile, biocompatible and cost-effective “tissue engineering”<sup>17</sup> modality, stimulating therapeutic uses in a variety of medical fields, including orthopedics, dentistry, ENT, neurosurgery, ophthalmology, urology, wound healing, as well as cosmetic, cardiothoracic and maxillofacial surgery.<sup>18</sup> Most recently, PRPP has found popular and effective applications in sports medicine, offering relief to two of the Pittsburgh Steelers’ biggest stars, Hines Ward and Troy Polamalu, as well as the golfer Tiger Woods, several major league pitchers, roughly 20 professional soccer players, and scores of recreational athletes. Of course the continued prevalence of sporting activities has generated an epidemic of musculoskeletal disorders, considering the fact that sports and athletics involve tremendous force: tennis players may serve continuously up to 140 miles per hour; pitchers throw a baseball 100 miles per hour, while marathon competitors run five minute miles for 26 miles,

and so on. It is therefore no wonder the body begins to break down, and attention must be focused on tendons, ligaments and joints, potentially establishing platelet rich plasma grafting techniques (PRPP) as one of the mainstay of tissue regeneration.

#### RATIONALE FOR PRPP

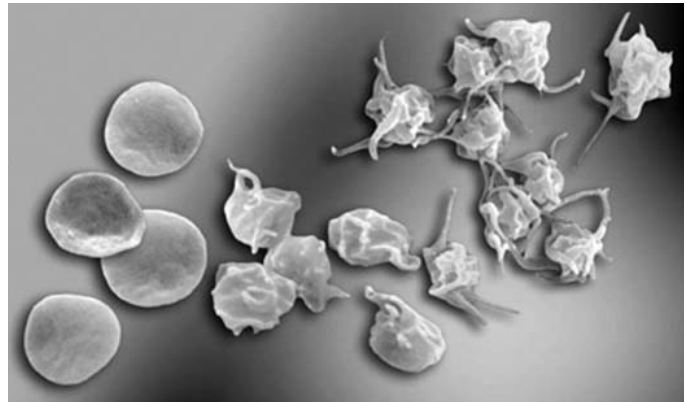
The PRPP benefit lies simply in supra-physiologic concentrations of platelets. To be precise, platelets compose less than 1% of blood, as their job is typically reserved for restoring hemostasis (stoppage of bleeding), construction of new connective tissue, and revascularization. Red blood cells (RBC), which primarily aid in delivering oxygen from lungs to other body cells, and white blood cells (WBC), which fight infections, kill germs and carry off dead blood cells, constitute 44% and 0.7% by volume of whole blood, respectively.<sup>19</sup> Namely, there are about one billion red blood cells in two to three drops of blood, and, for every 600 red blood cells, there are about 40 platelets and one white cell.<sup>20</sup> Plasma, the liquid component of blood made mostly of water and functions as a transporter for cells, composes the remaining 54.3% by volume of whole blood. The rationale for PRP benefits lies in reversing the blood ratio by decreasing RBC to 5%, which are less useful in the healing process, and increasing platelets to 94% to initiate recovery.<sup>21</sup> Naturally, platelet concentration is subject to slight variability due to manufacturer’s equipment.

To put it into perspective, 200,000 platelets/ul is the normal concentration, and as studies have demonstrated, clinical efficacy may be indicated with a minimum of 4x the baseline, which is the benchmark for “therapeutic PRP;” a count of 1 million/ $\mu$ L as measured in the standard 6-mL aliquot. Thus, platelet rich plasma is defined as a volume of plasma fraction of autologous (patient is both donor and receiver) blood, containing platelet concentration above baseline.<sup>22</sup> The autologous quality of PRP preparation eliminates any concerns of disease transmission or immunogenic reactions, which exist with allograft or xenograft preparations, given that the patient is both donor and recipient of the graft material.

The significant feature of platelets is the alpha granules, which organically promote healing of soft tissue by facilitating the release of one’s own growth factors; the process is simple and efficient since growth factors are readily available in significant amounts upon PRP activation. Normally at resting state thrombin is required

to trigger platelet activation, in turn prompting platelets to morph into strategic shapes,<sup>23</sup> develop branches, extend over injured tissue, and ultimately release growth factors that stimulate the inflammatory cascade and healing. (See Figure 1.) The main growth factors contained in the granules are transforming growth factor beta (TGF- $\beta$ ), which stimulates cell replication and fibronectin binding, vascular endothelial growth factor (VEGF), which is a potent stimulator of angiogenesis, platelet-derived growth factor (PDGF), which stimulates tissue remodeling, and epidermal growth factor (EGF), which induces cell migration and replication, amongst others. (See Table 1.) Combined, the growth factors play a critical role in the healing process and tissue regeneration, forming a cascade of diverse pathways, initiating activation of gene expression, and protein production. This specific feature of PRP directly addresses chronic non-healing tendon injuries, which traditional therapies approach with corticosteroid injections, medications like NSAIDs, and surgery; all of which, studies suggest, exhibit adverse side effects, ranging from atrophy, bleeding ulcers, and kidney damage, respectively.<sup>24</sup> In fact, it appears that the longer a musculoskeletal condition persists, the more resistant it becomes to traditional therapies; more over, it has been documented that protracted symptoms and relapses are regularly observed post conservative treatments.<sup>25</sup> So unlike traditional therapies, which ultimately treat tissue injuries without amending the inherent poorly healing properties or underlying pathology,<sup>26</sup> Platelet Rich Plasma Prolotherapy has been shown to enhance the early cascade of tissue repair processes both in vitro<sup>27</sup> and in vivo.<sup>28, 29</sup> Recent reports have accounted a more rapid epithelialization (coating of epithelial tissue), more dense and mature bone with better organized trabeculae (supporting strands of connective tissue), and greater bone regeneration occurring when PRPP is utilized in the treatment.<sup>30</sup>

The potent cocktail of growth factors containing a variety of biologic mediators can be applied directly to the healing site via Prolotherapy, an injection technique that has steadily gained widespread exposure as a form of pain management in both complementary and allopathic medicine. George S. Hackett, MD, who coined the term Prolotherapy<sup>31</sup> described it as “The treatment [which] consists of the injection of a solution within the relaxed ligament and tendon which will stimulate the production of new fibrous tissue and bone cells that will strengthen the ‘weld’ of fibrous tissue and bone to



**Figure 1. Active (right) and inactive (left) platelets.**  
Photo used with permission from University of Pennsylvania School of Medicine.

**Table 1. Growth factor chart.**

Used with permission from: Eppley BL, et al. Platelet quantification and growth factor analysis from platelet-rich plasma: implications for wound healing. *Plast Reconstr Surg.* 2004 November;114(6):1502-8.

<b>Platelet-derived growth factor (PDGF)</b>	<ul style="list-style-type: none"> <li>• Stimulates cell replication</li> <li>• Promotes angiogenesis</li> <li>• Promotes epithelialization</li> <li>• Promotes granulation tissue formation</li> </ul>
<b>Transforming growth factor (TGF)</b>	<ul style="list-style-type: none"> <li>• Promotes formation of extracellular matrix</li> <li>• Regulates bone cell metabolism</li> </ul>
<b>Vascular endothelial growth factor (VEGF)</b>	<ul style="list-style-type: none"> <li>• Promotes angiogenesis</li> </ul>
<b>Epidermal growth factor (EGF)</b>	<ul style="list-style-type: none"> <li>• Promotes cell differentiation &amp; stimulates re-epithelialization, angiogenesis &amp; collagenase activity</li> </ul>
<b>Fibroblast growth factor (FGF)</b>	<ul style="list-style-type: none"> <li>• Promotes proliferation of endothelial cells &amp; fibroblasts</li> <li>• Stimulates angiogenesis</li> </ul>

stabilize the articulation and permanently eliminate the disability.”<sup>32</sup> Physiologically speaking, this mode of treatment is particularly considerable since, as a result of mechanical factors, tendons and ligaments are vulnerable to injury and quite stubborn to heal. Expressly, tendons are composed of tenocytes, water, a variety of minor specialized cells, and millions of tightly woven fibrous collagen proteins, which form a durable strand of tissue, and naturally anchor to the bone to form a resilient mineralized connection. Ligaments are bands of tough, fibrous dense regular connective tissue comprising attenuated collagenous fibers connecting two bones, and are involved in the stability of the joint. The greatest amount of stress to ligaments and tendons is where they attach to bone: the fibro-osseous junction. Following

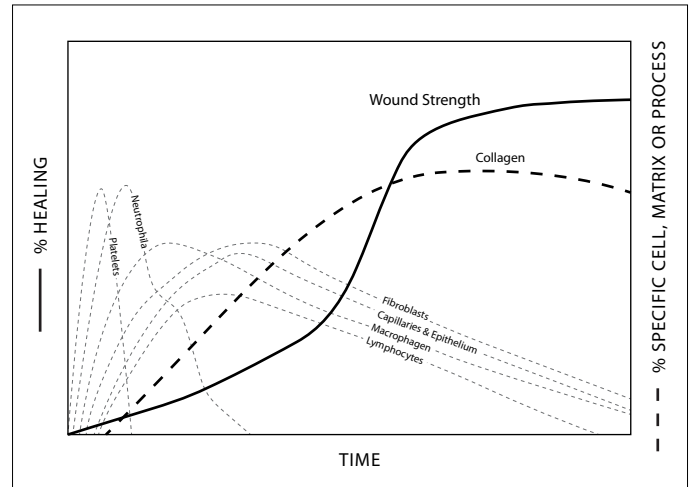
a ligament injury, resulting damage such as laxity may cause joint motion to become greater and offset the contact surface to regions where the cartilage may be thinner and less capable of supporting applied stresses, causing tremendous pain.<sup>33</sup> According to Daniel Kayfetz, MD, the most sensitive structures that cause pain are the periosteum (covering of bone) and ligaments. Dr. Kayfetz remarks that in the scale of pain sensitivity, the periosteum ranks first, followed by ligaments, tendons fascia, and finally muscle.<sup>34</sup>

Tendons and ligaments are particularly susceptible to injury when overwhelmed with the responsibility of transferring a great deal of force, repeatedly. Consequently, collagen fibers in the connective tissue may form micro tears and inflammation instigating conditions including tendinitis, or more appropriately, tendinosis, or tendinopathy.

<p><b>Tendinitis:</b> The suffix "itis" signifies inflammation, and applies to extensive, acute tendon injuries with accompanying inflammation.<sup>35</sup></p>
<p><b>Tendinosis:</b> The suffix "osis" signifies chronic degeneration without accompanying inflammation. Specifically, non-healing condition resultant from accumulation of microscopic injuries as the basis of pain and disability in chronically injured tendon tissue.<sup>36</sup> Tendinosis was first considered by German researchers in the 1940s; however, the term's more modern application relates to Puddu et al.<sup>37</sup> and Nirschl et al.<sup>38</sup></p>
<p><b>Tendinopathy:</b> The suffix "opathy" signifies no particular pathology, and may be applied to tendon injuries in general.</p>

Ligaments and tendons generally have a poor blood supply and heal at a comparatively slow rate, culminating in tissue scarring, which adversely affects function and increases risk of re-injury.<sup>39, 40</sup> Histologic samples from chronic cases indicate that an inflammatory response is not activated, but rather a limitation of the normal tendon repair system with a fibroblastic and a vascular response called angiofibroblastic degeneration.<sup>41, 42</sup> In the interest of embracing rather than suppressing the inflammation, PRPP injection prompts a local inflammation, triggering a wound healing cascade, and results in the deposition of new collagen, of which tendons and ligaments are composed. The new collagen contracts as it matures, in turn tightening and subsequently reinforcing the injected painful area. That is all the body requires, the remaining healing stages take care of themselves. They include: inflammation, proliferation and remodeling.<sup>43</sup>

Figure 2 depicts the cellular components involved in the three phases of healing.



**Figure 2. The physiology of healing of the chronic wound.**  
From [emedicine.com](http://emedicine.com). Image reprinted with permission from eMedicine.com, 2009.

During the primary inflammatory phase, the functions of activated platelets involve:

- Adhesion
- Aggregation
- Clot retraction
- Pro-coagulation
- Cytokine signaling
- Chemokine release
- Growth factor release
- Anti-microbial

Presently there is evidence to suggest that PRP grafts may be either anti-inflammatory or pro-inflammatory in specific tissue at certain concentrations, or dose-response curves.<sup>44</sup>

At the site of tissue injury, the latter exists to as yet an unknown PRP concentration and succeeding migration and proliferation of progenitor stem cells at the tissue injury site.<sup>45</sup>

Following the preliminary inflammatory phase, which generally lasts for two to three days, fibroblasts enter the site and commence the proliferative phase, which lasts from two to four weeks.<sup>46</sup> Fundamentally speaking, low pH and low oxygen levels encourage fibroblast proliferation in the injury site,<sup>47</sup> leading to the deposition of collagen and ground substances. Ultimately, the wound narrows

as actin contracts and fibroblasts differentiate into myofibroblasts. Given that fibroblasts are the primarily deficient cells with chronic injury, the proliferative phase is vital for musculoskeletal renewal. Appropriately, the PRPP grafts function via a triad of interactions, known as the cell proliferation triangle.<sup>48</sup> The last phase of this triangle involves the maturing and strengthening of collagen; essentially, tissue repair begins when the production and break down of collagen equalizes, a process which can last over one year. This remodeling period is characterized by type III collagen being replaced by type I collagen, reorganization, and disappearance of blood neovessels.<sup>49</sup> A competent Prolotherapy specialist ensures that each element of this triangle is present for effective tissue renewal and pain relief; otherwise, an incomplete or unabated stage results in loss of tissue homeostasis as well as pain and loss of function. Most reviews published on this matter tend to focus on growth factors contained within the platelet's alpha granules, but it is equally important to acknowledge that if platelets are not suspended with biologic levels of additional constituents of plasma, including cytokines, fibrin and leukocytes, then the graft may be either ineffective or less effective.<sup>50</sup>

**Matrix Graft:** A tissue graft incorporating autologous growth factors and/or autologous undifferentiated cells in a cellular matrix whose design depends on the receptor site and tissue of regeneration.<sup>51</sup>

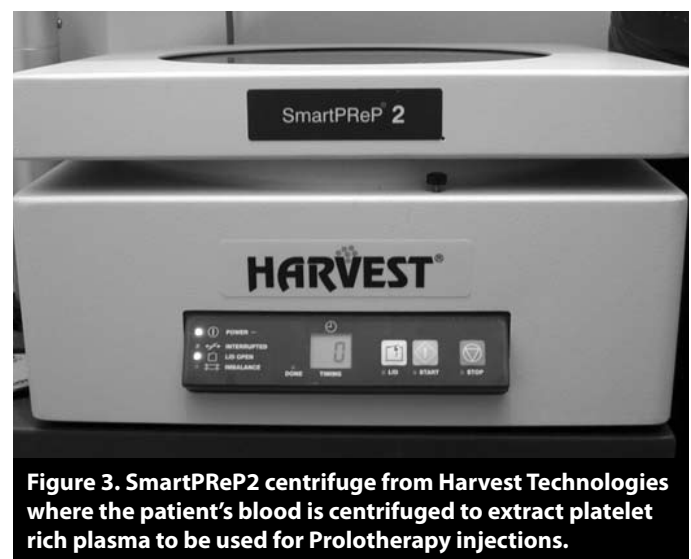On the other hand, if say fibrin levels are too high, or platelet activation occurs prior to collagen binding, the graft is likewise inhibited. Further functions of platelet activation and the subsequent cascade of events that develop include cytokine signaling, chemokine release and mitogenesis<sup>52</sup> (cell mitosis production). The active secretion of the growth factors typically begins within 10 minutes of being initiated by the clotting process of blood. Within one hour, approximately 95% of the pre-synthesized growth factors are secreted.<sup>53</sup>

#### PLATELET RICH PLASMA PROCESSING

While the standard proliferant utilized in Prolotherapy is typically dextrose-based, platelet rich plasma is growing in popularity and with it the various PRP preparation techniques. Gradient density cell separation and concentration of platelets from autologous whole blood varies from the use of test tube collection and laboratory

centrifuges to the more sophisticated device employing a floating shelf technology.

Though in essence the end goal of platelet sequestering devices is akin, parameters such as viability, functionality, quantity of platelets, as well as concentration of growth factors should be confirmed by a scholarly, peer-reviewed journal. Studies asserting lack of PRP benefits can often be traced to poor-quality PRP produced by inadequate devices. More over, studies presenting little benefit from PRP often use damaged or inactivated platelets, and have statistically insufficient data to draw a valid conclusion. For example, an article by Froum et al.<sup>54</sup> included only three patients and introduced multiple independent variables to confound their results; in addition, the study did not test the platelet concentrations as other studies. Weibrich and Klies<sup>55</sup> documented the inadequacies of various devices that may contribute to poor trial results, finding them to be deficient in developing therapeutic levels of platelets compared to quality devices like the Harvest SmartPReP2 platelet concentrate system as well as Biomet Biologics GPS III system, described here for simplicity. (See Figure 3.) Approximately 30 to 60ml of venous blood is drawn from the antecubital (bend of arm) vein using the aseptic technique; an 18 or 19G butterfly needle is advised in efforts to prevent trauma to the platelets, which are at resting state. Subsequently, blood is placed in an FDA approved, sterile centrifuge and spun for 15 minutes at 3,200 rpm, separating blood into platelet poor plasma (PPP), RBC and PRP. (See Figure 4.) While the PPP is discarded through a special port, the PRP is shaken in a vacuumed space for 30 seconds to re-suspend the platelets. Clinical studies established that an increase of three to four fold above



**Figure 3. SmartPReP2 centrifuge from Harvest Technologies where the patient's blood is centrifuged to extract platelet rich plasma to be used for Prolotherapy injections.**



**Figure 4. Blood after being centrifuged allows the clinician to extract the platelet rich plasma to be used for injection.**

baseline as an acceptable standard.<sup>56</sup> Haynesworth et al.<sup>57</sup> demonstrated that the proliferation of adult mesenchymal stem cells and their differentiation were directly related to the platelet concentration, particularly showing a dose-response curve, which indicated that an adequate cellular response to platelet concentrations first began when a four to five fold increase over baseline platelet numbers was achieved.

Weibrich et al. observed an advantageous effect with platelet concentrations of approximately  $106/\mu\text{L}$ . Further they state that higher concentrations might have a paradoxically inhibitory effect.<sup>58</sup> A study by Lui et al. demonstrated that type I collagen production and fibroblast were enhanced by just the right concentration of platelets, ultimately emphasizing the importance of qualified devices.<sup>59</sup> Once the PRP is expertly yielded, it may remain sterile and the concentrated platelets viable for up to 8 hours, ready for injection. Considering the data from imaging studies such as MRI and radiographs, as well as clinical exams and the highly recommended dynamic musculoskeletal ultrasound with a transducer of 6 to 13 Hz, the area of injury is marked and directly injected with or without an appropriate anesthetic, such as lidocaine or marcaine. In addition to the local anesthetics, physicians

may further assist patients, who find Prolotherapy painful, by prescribing Tylenol® or Vicodin® to be taken prior to Prolotherapy treatments. Some physicians may use an anesthetic cream that is rubbed on the specific area, thereby decreasing pain of needle injection. Some spray an anesthetic like lidocaine on the skin, or inject some anesthetic into the skin to abate pain associated with a needle piercing skin, which some patients complain is the most painful part of the procedure. Of course the pain intensity varies from patient to patient during the Prolotherapy treatment. However, the consensus remains that it's minimal compared to untreated chronic pain endured by patients on a daily basis.

Soreness following PPRP is commonly experienced since the injections must travel through some muscles to access ligaments and tendons. Between the second and fourth weeks, called the “window period” of healing, initial stabilization induced by PPRP subsides and because the initial growth of tissue is incomplete, some of the original pain may return. To ensure an accurate evaluation of results, follow-up is typically recommended four to six weeks after each treatment, thus avoiding patient evaluation within the “window period” of healing. To facilitate swift sore muscle resolution, massage therapy and moist heat applied to the area is recommended. Nutritional products to encourage soft tissue healing, such as bromelain, MSM, and high potency enzymes, are sometimes recommended. Gentle manipulation techniques, such as myofascial release, strain-counter-strain, or activator gun treatments, may be helpful as well. Other modalities that improve circulation and assist the healing from PPRP include acupuncture, Rolfing, electrical stimulation, magnets, infrared heat, and ultrasound.<sup>60</sup> It is important to note that for PRPP to be most effective, patients should avoid anti-inflammatory medications to ease pain, as they may be counter-productive to the underlying PRPP recovery process. Narcotic medications, such as Vicodin, Tylenol with Codeine, and Darvocet, should be avoided on account of their immune-suppressive properties, which too is counter-productive since the immune system is critical for healing following PPRP.<sup>61, 62</sup>

There is extensive documentation of both animal and human studies, with widespread applications, demonstrating the safety and efficacy of properly managed PRPP. Though most studies to date are pilot designs with small sample sizes, recently emerging literature demonstrates beneficial effects of PRPP for chronic non-

healing tendon injuries including lateral epicondylitis, plantar fasciitis<sup>63, 64</sup> as well as knee ligaments, rotator cuff tears, wound healing, Achilles tendon tears, anterior cruciate ligaments (ACL), amongst others. There is also a range of publications in other fields including ENT, cardiology and plastic surgery. The following is a review of some of the more recent studies of PRPP.

#### ELBOW

Medically classified as lateral epicondylitis, tennis elbow is characterized by tissue degeneration of the wrist and forearm extensor tendons at the elbow. Commonly, injuries are caused by mechanical overloading<sup>65</sup> of the forearm muscles, constant repeated actions associated with racquet sports, manual work in which twisting hand movements are involved, weight training, a variety of other traumatic movement of the elbow or wrist, and abnormal micro-vascular responses.<sup>66</sup> Histologic specimens from chronic cases confirm that tendinosis is not an acute inflammatory condition but rather a failure of the normal tendon repair mechanism associated with angiofibroblastic degeneration.<sup>67</sup> An estimated four in 1,000 individuals are affected with this condition at some time,<sup>68</sup> and is a frequent cause of missed work.<sup>69, 70</sup>

Numerous methods have been advocated for treating elbow tendinosis, including rest, non-steroidal anti-inflammatory medication, bracing, physical therapy, iontophoresis,<sup>71</sup> extracorporeal shock wave therapy, and botulism toxin.<sup>72</sup> Corticosteroid injections have been used extensively in this case, but studies show that there is conflicting evidence about their efficacy.<sup>73, 74</sup> In February 2011, *Orthopedics* published a study<sup>75</sup> demonstrating the efficacy of a single PRP injection for recalcitrant common extensor or flexor tendons, otherwise unresponsive to nonsurgical treatments like steroid injections. Such promising results were further substantiated in a double-blind, randomized controlled trial published in *The American Journal of Sports Medicine*. One-hundred patients with chronic lateral epicondylitis, randomly assigned to a leukocyte-enriched PRP or corticosteroid group, demonstrated significantly increased function and reduced pain in the PRP group, "exceeding the effect of corticosteroid injection even after a follow-up of 2 years."<sup>76</sup> The next Prospective Cohort study, also documented in the *American Journal of Sports Medicine*, evaluated the use of platelet rich plasma as a treatment for chronic severe epicondylar tendinosis. Mishra et al. examined 140 patients, 20 of whom met the study criteria

and were surgical candidates who had previously failed conservative therapies. Of those, five were controls treated with local anesthetic bupivacaine, while the remaining 15 study subjects received one PRP injection. Notably, the study group observed 60% improvement in their visual analog pain scores at 8 weeks, 81% improvement in their visual analog pain scores (P=0.001) at 6 months, and 93% at final follow-up at 12-38 months (mean, 25.6 months; range, 12-38 months). Markedly there were no adverse effects or complications, with a 94% return to sporting activities, and a 99% return to daily activity.<sup>77</sup> Confoundings are limited to 60% attrition rate in the control group as 3/5 of the subjects withdrew from the study or sought outside treatment at eight weeks.

In 2003, Edwards and Calandruccio demonstrated that 22 of 28 (79%) subjects with refractory chronic epicondylitis were entirely pain free following autologous blood injection therapy.<sup>78</sup> The 28 patients were followed-up for an average of 9.5 months (range 6-24 mo.). Before autologous blood injections, the average pain score was 7.8 (range 4-10). The average Nirschl stage was 6.5 (range 5-7). Following autologous blood injections the average pain score decreased from 7.8 to 2.3 while the average Nirschl stage decreased from 6.5 to 2.0. Of note, there was no reported worsening or recurrence of pain and no other adverse events. Pain following buffered PRP injection was variable, but comparable to prior steroid injections subjects received before the study. Lack of control group and small sample size limits this study.

#### FOOT

Plantar fasciitis is a common cause of heel pain, potentially resulting in pathologic degenerative tissue changes, similar to tennis elbow. It has been estimated that in a typical podiatric practice, approximately 40% of patients complain of heel pain. Severe or prolonged cases of plantar fasciitis may result in partial or full thickness tearing of the plantar fascia, which encapsulates the muscles in the sole of the foot. This very important connective tissue is responsible for supporting the arch of the foot and endures tension that is approximately two times body weight. Barrett et al. enrolled nine patients in a pilot study to evaluate PRP injections for plantar fasciitis. Patients met the criteria upon willingness to avoid conservative treatments such as NSAIDs, bracing and cortisone injection for 90 days prior. Ultrasound confirmed that all patients demonstrated hypoechoic and thickened plantar

fascia. Following a 3cc of autologous PRP injection under ultrasound guidance, thickness and increased signal intensity of the fascial bands were observed. Six of nine patients achieved complete symptomatic relief following a period of two months. One of three unsuccessful patients eventually found complete relief following an additional PRP injection. At one year, 77.9% patients had complete resolution of symptoms.<sup>79</sup>

#### ACHILLES

The Achilles tendon is located in the back of the leg and attaches to the heel bone (calcaneus.) It is the largest and strongest tendon in the body, enabling elevating on the toes and jumping. Achilles tendinitis may occur from wearing inappropriate footwear, or from repetitive jumping especially on poor surfaces, eventually causing either acute or chronic injury. The former is characterized by inflammation while in chronic cases there is degeneration of the tendon fibers that may progress to a partial or complete tear.

In a study conducted by Per Aspenberg and Olena Virchenko,<sup>80</sup> platelet concentrate injection was shown to improve Achilles tendon repair in an established model of 296 Sprague-Dawley rats. The Achilles tendon was transected (cut across) and a 3mm segment removed. Following six hours, a platelet concentrate was injected percutaneously (needle puncture of skin) into the hematoma (clotted blood caused by break in blood vessel). This increased tendon callus strength as well as stiffness by roughly 30% following a one week period, persisting for as long as three weeks post injection. At this time, the mechanical testing indicated an improvement in material features, i.e., greater maturation of the tendon callus. Ultimately, it may be interpreted that platelet concentrate may prove useful for the treatment of Achilles tendon ruptures.

Sanchez et al. reported on a case control study of 12 athletes with complete Achilles rupture.<sup>81</sup> The athletes similarly had open Achilles repair; specifically, six had PRGF, while the treatment group showed no wound complications and experienced earlier functional restoration: ROM (seven vs. 11 wks.), jogging (11 vs. 18 wks.) and training (14 vs. 21 wks.). The authors measured IGF-I, TGF- $\beta$ 1, PDGF-AB, EDF, VEGF and HGF, and noted that the number of platelets were directly correlated to the level of growth factors, and improved collagen organization. More data demonstrating positive outcomes following

PRP injections for Achilles tendinopathy is presented by Robert J. de Vos et al. in a stratified, block-randomized, double-blind, placebo-controlled trial.<sup>82</sup> Fifty-four patients, aged 18 to 70 years, with chronic tendinopathy 2 to 7 cm above the Achilles tendon insertion were randomized into a PRP group (control) or saline injection group (placebo), accompanied by eccentric exercises. Treatment outcomes were measured using a Victorian Institute of Sports Assessment-Achilles (VISA-A) questionnaire, which specifically evaluated pain score and activity level at baseline as well as 6, 12 and 24 weeks, with higher scores corresponding to less pain and increased activity. Following 24 weeks, the mean VISA-A score improved considerably in the PRP group by 21.7 points and in the placebo group by 20.5 points. While the increase was not significantly different between control and placebo groups, improvement in pain and activity following PRP injection was significant in its own right. Yelland et al. conducted a similar randomized study, comparing the effectiveness of single or combined use of eccentric exercise with Prolotherapy to treat painful mid-portion Achilles tendinosis. Over a 12 month period, the main outcome of the 43 patients was prospectively measured using the VISA-A questionnaire, focusing on pain, stiffness and limitation of activity; at 12 months, the percentage of participants achieving the minimum clinically important change (MCIC) was 73% for eccentric load exercise, 79% for Prolotherapy, and 86% for combined treatment. The study concluded that compared with eccentric load exercise alone, reduction in stiffness and limitation of activity occurred earlier with Prolotherapy, while pain was additionally reduced earlier with combined treatment.<sup>83</sup>

#### KNEE

Lesions of anterior cruciate ligament (ACL) represents one of the most common traumas in sporting practice, ranging from 75,000 to 100,000 cases per year in the United States.<sup>84</sup> The loss of the knee center rotation following ACL lesions causes a functional overload, leading to cartilage defects, meniscal lesions and early gonarthrosis. It is worth recalling that the blood supply is from within the ligament as opposed to around it; therefore, blood supply is commonly disrupted during injury when the ligament is torn.<sup>85</sup> ACL injuries may be attributed to sports including football, soccer and basketball where deceleration and swift cutting movements are common; knee joints are particularly vulnerable to such trauma and subsequent ligament injury on account of their location between the two longest lever arms in the body, tibia and femur, which



experience high repetitive impact loads.<sup>86</sup> ACL and medial collateral ligament (MCL) may both sustain an injury if, say, an athlete is struck by another from behind and outside. Such injury is often accompanied by an audible “pop” usually with, though occasionally without, pain.<sup>87</sup> Untreated, relaxed, or torn ACLs have been shown to precipitate degeneration of the meniscus and eventual degenerative osteoarthritis,<sup>88</sup> given the decreased joint stability and alteration of biomechanical forces.

**Meniscus:** *The meniscus primarily distributes stresses and forces evenly across the knee joint, though in a compromised state, contact forces increase over a smaller area of cartilage causing abrasion, and ultimately joint degeneration.*

The combination meniscal injury incurred at time of ACL damage is very commonly associated with knee osteoarthritis<sup>89</sup> considering biomolecular damage to type II collagen and an initial increase in proteoglycan content.<sup>90</sup>

**Proteoglycan:** *cementing like glycoproteins occurring in connective tissue, influencing both activity and stability of proteins as well as signaling molecules within the extracellular matrix.<sup>91</sup>*

In other words, stressors change anatomy of a joint creating an unfavorable environment for other structures like meniscus, ligaments and cartilage. In a single-center, uncontrolled, prospective preliminary study, Sampson et al. evaluated the clinical effects of intra-articular PRP injections in a small group of participants with primary and secondary knee osteoarthritis. Outcome measures included the Brittberg-Peterson Visual Pain (Visual Analog Scale [VAS]), Activities, and Expectations score and the Knee Injury and Osteoarthritis Outcome Scores at preinjection visit and at 2-, 5-, 11-, 18-, and 52-week follow-up visits. Scores demonstrated significant and nearly linear improvements in knee pain and symptom relief, with majority of patients expressing a favorable response at 12 months following treatment.<sup>92</sup>

A prospective pilot study conducted by Ventura et al.<sup>93</sup> evaluated the efficacy of using platelet rich plasma growth factors as a potential treatment in anterior cruciate ligament surgery. Twenty patients with laxity caused by torn ACL underwent arthroscopically assisted reconstruction with autologous quadrupled hamstring

tendon graft (QHTG). Platelet gel was applied in the femoral and tibial tunnels. The rehabilitation protocol standardized for both randomized growth factor group and control, included: immediate postoperative mobilization without a knee brace, protected weight bearing for three weeks, and return to sporting activities at six months, during which time patients were evaluated both clinically and functionally. CT highlighted a significant difference ( $P < 0.01$ ) between ACL density of the two groups. At six months following surgery, the ACL density between the PRP treated group and control was noticeably different, with the treated group exhibiting uniform density and improved structure. In the control, the ligament was less structured and incompletely filled the femoral and tibial tunnels. As this study demonstrates, PRP based growth factors may accelerate the integration of the new ACL in the femoral and tibial tunnels.

Following a PRP injection in rat patellar tendons, Kajikawa et al. demonstrated increased quantity of circulation-derived cells in the early phase of tendon repair after injury, versus controls.<sup>94</sup> With respect to other animal studies, a rabbit patella tendon was ruptured and subsequently sealed with platelet-rich plasma gel; after three weeks, a histological examination showed swift recovery with particular emphasis on angiogenesis earlier in the healing process, more mature and dense vessels and greater fiber elasticity.<sup>95</sup> In a human model, Kon et al.<sup>96</sup> examined the role of PRP in treating jumper’s knee, a condition characterized by microscopic ruptures in Patellar tendon commonly in high-impact jumping sports. In this prospective pilot study, participants were all male athletes with a mean age of 25.5 years, for whom both surgery and nonsurgical treatments like steroid injections had little effect. At six month follow-up, functional recovery indicated six participants with complete recovery, eight with marked improvement, and six cases with mild to no improvement. Ultimately, statistically significant recovery from pre-treatment levels to six months was observed, with improved knee function and quality of life, marked satisfaction and return to sport.

#### ROTATOR CUFF

Rotator cuff injury of one or more of the four shoulder muscles can range from inflammation without any permanent damage, such as tendonitis, to a complete or partial tear of the muscle that might require surgery. Rotator cuff surgery is one of the most common

procedures performed by orthopedic surgeons, with over 250,000 performed annually in the United States alone. The tendons of the rotator cuff, not the muscles, are most commonly torn. Of the four tendons, the supraspinatus is most frequently torn, usually occurring at its point of insertion onto the humeral head at the greater tuberosity.<sup>97</sup> The poor healing capacity of the torn rotator cuff is well known. Once torn, the injury either remains the same size or expands in size with time.<sup>98</sup> In a prospective study conducted by Scarpone et al.,<sup>99</sup> 14 patients had rotator cuff tears with no significant AC joint thickness with impingement and no other significant symptomatic pathology. It must be noted that all 14 patients, strongly considering surgical options, failed non-operative treatments, including NSAIDs, physical therapy, and corticosteroid injections. In the study, skin was anaesthetized with 1% xylocaine and under ultrasound guidance; 3ml of autologous platelet concentrate (APC) was injected directly into the tendon sheath at the injury site. The PRPP effect was measured radiographically with MRI, strength and endurance was tested and patients underwent an analog pain scale. Each measurement was carried out prior to PRP injection, four weeks post-injection, and eight weeks post-injection. Results demonstrated 12 of 14 subjects statistically significant improvements in pain scale and strength, as well as endurance at eight weeks. Of the 12 patients, six had radiographic evidence of healing of their tendinopathy on MRI at eight weeks. Of the four patients who were considering surgery due to persistent pain, two went on to have rotator cuff surgery. No acute complications associated with the procedure occurred.

Reflecting on all the aforementioned conditions that PRP Prolotherapy serves, anecdotal evidence suggests that the procedure emerges as an unparalleled low-risk, natural and highly-effective nonsurgical solution that triggers the body's own healing capacity.

## DISCUSSION

The United States *Bone and Joint Decade* has successfully spotlighted musculoskeletal injuries, which, despite being more prevalent than conditions like heart disease, cancer and respiratory problems, still fail to receive the same attention on account of associated death rarity. Nevertheless, awareness of the growing burden of related disorders on society has been raised, focusing close attention on injuries like sprains and strains commonly incurred during sudden movement or excessive use (16.3

million injuries in 2004); fractures (15.3 million); open wounds, cuts and punctures (10.3 million); and contusions and bruises (8.4 million). In 2005, 107.7 million adults, one in two aged 18 and over, reported suffering from a musculoskeletal condition lasting three months or longer during the past year. According to the *Burden of Musculoskeletal Disease in the United States*, “this is nearly twice the number who reported any other medical condition. In addition, nearly 15 million adults reported they were unable to perform at least one common activity, such as self-care, walking, or rising from a chair, on a regular basis due to their musculoskeletal condition.”<sup>100</sup>

The conveniently obtainable PRP and the strikingly straightforward, simple to perform Prolotherapy injection procedure holds promise to harness the body's natural healing power by effectively supercharging one's own capacity for tissue regeneration. So while conventional treatments for soft tissue injury like NSAIDs and steroid injections seek to decrease painful symptoms by reducing inflammation, PRPP embraces this process and in turn initiates growth of new tissue and collagen, ultimately correcting injury as opposed to symptoms. This method of treatment repeatedly demonstrates successful outcomes for a variety of conditions. PRPP may come to be considered a logical first step of treatment prior to, or possibly instead of, surgical intervention for some injuries. This treatment is important to alleviate pain and disability particularly at a time when the current trend estimates 61 million persons at risk of musculoskeletal disease by 2020.<sup>101</sup> Approximately 1 in 10 injuries ensues during sports activities, and another one in 10 in automobile or pedestrian accidents.<sup>102</sup> So whether a person is a working professional determined to promptly resume work, a weekend warrior eager to get back in the game, or simply long to recommence daily activities, PRPP offers new hope for natural healing. “It's a better option for problems that don't have a great solution—it's nonsurgical and uses the body's own cells to help it heal,” says Dr. Allan Mishra, an assistant professor of orthopedics at Stanford University Medical Center and one of the primary researchers in the field. “I think it's fair to say that PRP has the potential to revolutionize not just sports medicine but all of orthopedics. It needs a lot more study, but we are obligated to pursue this.” Scores of studies are currently underway to elucidate questions that still remain unanswered regarding long-term stability of this procedure and the possible modifications that can still be done to achieve even better results. ■

## REFERENCES:

1. Lynch S, et al. Role of platelet-derived growth factor in wound healing: synergistic effects with other growth factors. *Proc Natl Acad Sci.* 1987;84:7696-7700.
2. Sampson S, et al. Platelet rich plasma injection grafts for musculoskeletal injuries review. *Curr Rev Musculoskelet Med.* 2008;1:165-174.
3. Woolf A, et al. Burden of major musculoskeletal conditions. *Bull World Health Organ.* 2003;81:646-656.
4. United States Bone and Joint Decade: *The burden of musculoskeletal diseases in the United States.* Rosemont IL: American Academy of Orthopaedic Surgeons; 2008.
5. National Center for Health Statistics, National Health Interview Survey, 2005.
6. Arnold M, et al. The pharma report: top 20 pharma companies. *Medical Marketing & Media.* 2008;45-55.
7. Arthritis Foundation Web site. Available at <http://arthritis.org/cost-arthritis.php>. Accessed on Oct 4, 2011.
8. Brody J. Personal Health; A new set of knees comes at a price: a whole lot of pain. *New York Times.* 2008. published February 8, 2005.
9. Praemer A. Musculoskeletal conditions in the United States. 2nd ed. *Rosemont: American Academy of Orthopaedic Surgeons;* 1999.
10. Wheaton M, et al. The ligament injury connection to osteoarthritis. *Journal of Prolotherapy.* 2010;2(1):294-304.
11. Kujala U, et al. Knee osteoarthritis in former runners, soccer players, weight lifters and shooters. *Arthritis and Rheumatism.* 1995;38(4):539-546.
12. Felson D. Arthroscopy as treatment for knee osteoarthritis. *Best Pract Res Clin Rheumatol.* 2010;24(1):47-50.
13. White A, et al. Direct and indirect costs of pain therapy for osteoarthritis in an insured population in the United States. *Journal of Occupational and Environmental Medicine.* 2008;50(9): 998-1005.
14. Kader D, et al. Achilles tendinopathy: some aspects of basic science and clinical management. *Br J Sports Med.* 2002;36:239-49.
15. Anitua E, et al. The potential impact of the preparation rich in growth factors (PRFG) in different medical fields. *Biomaterials.* 2007;28:4551-4560.
16. Ferrari M, et al. A new technique for hemodilution, preparation of autologous platelet-rich plasma and intra-operative blood salvage in cardiac surgery. *Int J Artif Organs.* 1987;10:47-50.
17. Vacanti J, et al. Tissue engineering: the design and fabrication of living replacement devices for surgical reconstruction and transplantation. *Lancet.* 1999;354:32-34.
18. Weibrich G, et al. Growth factor levels in platelet-rich plasma and correlations with donor age, sex, and platelet count. *J Craniomaxillofacial Surg.* 2002;30:97-102.
19. Sylvia S. Mader. *Biology Seventh Edition.* New York, NY; McGraw Hill Companies, Inc.; 2001.
20. Ignatavicius D, et al. *Medical-Surgical Nursing: A Nursing Process Approach.* Philadelphia, PA: W. B. Saunders Company; 1991.
21. Marx R, et al. *Dental and craniofacial applications of platelet rich plasma.* Carol Stream: Quintessen Publishing Co, Inc.; 2005.
22. Pietrzak W, et al. Scientific foundations platelet rich plasma: biology and new technology. *J Craniofac Surg.* 2005;16(6):1043-54.
23. Canalis E, et al. Effects of platelet-derived growth factor on bone formation in vitro. *J Cell Physiol.* 1989;140:530-537.
24. Jobe F, et al. Lateral and medial epicondylitis of the elbow. *J Am Acad Orthop Surg.* 1994;2:1-8.
25. Alternative treatments: dealing with chronic pain. *Mayo Clinic Health Letter.* April 2005;23(4).
26. Antua E, et al. Autologous fibrin matrices potential source of biological mediators that modulate tendon cell activities. *J Biomed Mater Res Pt A.* 2006;(2):285-93.
27. Stephen E, et al. Platelet-derived growth factor enhancement of a mineral-collagen bone substitute. *J Periodontol.* 2000;71:1887-1892.
28. Lynch S, et al. The effects of short-term application of a combination of platelet-derived and insulin-like growth factors on periodontal wound healing. *J Periodontol.* 1991;62:458-467.
29. Stefani C, et al. Platelet-derived growth factor/insulin-like growth factor-1 around implants placed into extraction sockets: a histometric study in dogs. *Implant Dent.* 2000;9:126-132.
30. Marx R, et al. Platelet-rich plasma: growth factor enhancement for bone grafts. *Oral Surg Oral Med Oral Pathol Oral Radiol Endod.* 1998;85:638-646.
31. Hackett G. Referral pain and sciatica in diagnosis of low back disability. *JAMA.* 1957;163:183-185.
32. Hackett G, et al. *Ligament and Tendon Relaxation Treated by Prolotherapy. Third Edition.* Springfield, IL. 1958.
33. Andriacchi T, et al. A framework for the in vivo pathomechanics of osteoarthritis at the knee. *Annals of Biomedical Engineering.* 2004;32(3):447-457.
34. Kayfetz D. Occipital-cervical (whiplash) injuries treated by Prolotherapy. *Medical Trial Technique Quarterly.* 1963;9-29.
35. Khan K, et al. Overuse tendinosis, not tendonitis. *The Physician and Sports medicine.* 2000;28(5):38-48.
36. Khan K, et al. Histopathology of common tendinopathies: update and implications for clinical management. *Sports Medicine.* 1999;27:393-408.
37. Puddu G, et al. A classification of Achilles tendon disease. *American Journal of Sports Medicine.* 1976;4:145-150.
38. Nirschl R, et al. Tennis elbow: the surgical treatment of lateral epicondylitis. *Journal of Bone and Joint Surgery (Am).* 1979;61:832-839.
39. Fenwick S, et al. The vasculature and its role in the damaged and healing tendon. *Arthritis Res.* 2002;4:252-60.
40. Browner, B. et al. *Skeletal Trauma.* Philadelphia, PA: W.B. Saunders Company, 1992;1:87-88.
41. Mishra A, et al. Treatment of chronic elbow tendinosis with buffered platelet rich plasma. *Am J Sports Med.* 2006;10(10):1-5.
42. Edwards S, et al. Autologous blood injections for refractory lateral epicondylitis. *Am J Hand Surg.* 2003;28(2):272-8.
43. Kumar V, et al. Chapter 2- Acute and chronic inflammation. In: Robbins and Cotran *Pathologic Basis of Disease.* 7th ed. 2005 Saunders.

44. El-Sharkawy H, et al. Platelet-rich plasma: growth factors and pro-and-anti-inflammatory properties. *J Periodontol.* 2007;78:661-669.
45. Haynesworth S, et al. Mitogenic stimulation of human mesenchymal stem cells by platelet releasate. Poster Presentation, *American Academy of Orthopedic Surgery.* March 2001.
46. Quinn J. (1998). *Tissue Adhesives in Wound Care.* Hamilton, Ont. B.C. Decker, Inc. Electronic book.
47. Liu Y, et al. Fibroblast proliferation due to exposure to a platelet concentrate in vitro is pH dependent. *Wound Rep Reg.* 2002;10:336-340.
48. Barnett M, et al. Use of platelet rich plasma and bone marrow derived mesenchymal stem cells in foot and ankle surgery. *Techniques in Foot and Ankle Surgery.* 2007;6(2):89-94.
49. Komarcevic A. The modern approach to wound treatment. *Med Pregl.* Jul-Aug 2000;53:363-8.
50. Everts P, et al. Platelet-rich plasma and platelet gel: a review. *JECT.* 2006;38:174-187.
51. Crane D, et al. Platelet rich plasma (PRP) matrix grafts. *Practical Pain Management.* January/February 2008;1-10.
52. Kumar V, et al. Acute and chronic inflammation. In: Robbins and Cotran, eds. *Pathologic Basis of Disease.* 7th ed. Saunders; 2005.
53. Kevy S, et al. Preparation of growth factors enriched autologous platelet gel. Proceedings of the 27th Annual Meeting of Service Biomaterials, April 2001.
54. Froum S, et al. Effect of platelet rich plasma on bone growth and osseointegration in human maxillary sinus grafts: three bilateral case reports. *Int J Periodont Restor Dent.* 2002;22:45.
55. Weibrich G, et al. Curasan PRP kit vs. PCCS PRP system: collection efficiency and platelet counts of two different methods for the preparation of platelet rich plasma. *Clin. Oral Implant Res.* 2002;13:437.
56. Marx R, et al. Platelet rich plasma: a primer. *Practical Pain Management.* March 2008.
57. Haynesworth S, et al. Mitogenic stimulation of human mesenchymal stem cells by platelet release suggest a mechanism for enhancement of bone repair by platelet concentrates. Presented at the 48th Meeting of the Orthopedic Research Society. Boston, MA, 2002.
58. Weibrich G, et al. Effect of platelet concentration in platelet rich plasma on peri-implant bone regeneration. *Bone.* 2004;34:665-671.
59. Tiozzi R, et al. PRP: A possibility in regenerative therapy. *Int Journal of Morphology.* 2007.
60. Hauser R. Caring Medical website. Available at: <http://www.caringmedical.com/therapies/Prolotherapy-info/soreness.asp>. Accessed on May 25, 2010.
61. Manchikanti L, et al. Therapeutic opioids: a 10 year perspective on complexities and complications of the escalating use, abuse, and non-medical use of opioids. *Pain Physician.* 2008;11(2 Suppl):S63-88.
62. Eisenstein T. Opioid modulation of immune responses: effects of phagocyte and lymphoid cell populations. *Journal of Neuroimmunology.* 1998;83:36-44.
63. Mishra A, et al. Treatment of chronic elbow tendinosis with buffered platelet-rich plasma. *Am J Sports Med.* 2006;10(10):1-5.
64. Barrett S, et al. Growth factors for chronic plantar fasciitis. *Podiatry Today.* 2004;17:37-42.
65. Wang J, et al. Biomechanical basis for tendinopathy. *Clin Orthop Relat Res.* 2006;443:320-332.
66. Smith R, et al. Abnormal microvascular responses in lateral epicondylitis. *Br J Rheum.* 1994;33:1166-1168.
67. Jobe F, et al. Lateral and medial epicondylitis of the elbow. *J Am Acad Orthop Surg.* 1994;2:1-8.
68. Hamilton P. The prevalence of humeral epicondylitis: a survey in general practice. *J R Coll Gen Pract.* 1986;36:464-465.
69. Labelle H, et al. Lack of scientific evidence for the treatment of lateral epicondylitis of the elbow. *J Bone Joint Surg Br.* 1992;74:646-651.
70. Dimberg L. The prevalence and causation of tennis elbow in a population of workers in an engineering industry. *Ergonomics.* 1987;30:573-579.
71. Nirschl R, et al. Iontophoretic administration of dexamethasone sodium phosphate for acute epicondylitis: a randomized, double-blinded placebo-controlled study. *Am J Sports Med.* 2003;31:189-198.
72. Keizer S, et al. Botulinum toxin injection versus surgical treatment for tennis elbow. *Clin Orthop relat Res.* 2002;401:125-131.
73. Altay T, et al. Local injection treatment for lateral epicondylitis. *Clin Orthop Relat Res.* 2002;398:127-130.
74. Newcomer K, et al. Corticosteroid injection in early treatment of lateral epicondylitis. *Clin J Sports Med.* 2001;11:214-222.
75. Hechtman K, et al. Platelet-rich plasma injection reduces pain in patients with recalcitrant epicondylitis. *Orthopaedics.* 2011;34(2):92.
76. Gosens T, et al. Ongoing positive effect of platelet rich plasma versus corticosteroid injection in lateral epicondylitis: a double-blind randomized controlled trial with a 2 year follow-up. *The American Journal of Sports Medicine.* 2011;39(6):1200-8.
77. Mishra A, et al. Treatment of chronic elbow tendinosis with buffered platelet-rich plasma. *Am J Sports Med.* 2006;10(11):1774-1778.
78. Edwards S, et al. Autologous blood injections for refractory lateral epicondylitis. *Am J Hand Surg.* 2003;28(2):272-8.
79. Barrett S, et al. Growth factors for chronic plantar fasciitis. *Podiatry Today.* 2004;17:37-42.
80. Aspenberg P, et al. Platelet concentrate injection improves Achilles tendon repair in rats. *Acta Orthop Scand.* 2004;75(1):93-99.
81. Sanchez M, et al. Comparison of surgically repaired Achilles tendon tears using platelet rich fibrin matrices. *Am J Sports Med.* 2007;35(2):245-251.
82. Vos Robert J, et al. Platelet rich plasma injection for chronic Achilles tendinopathy. *JAMA.* 2010;303(2):144-149.
83. Yelland M, et al. Prolotherapy injections and eccentric loading exercises for painful Achilles tendinosis: a randomised trial. *Br J Sports Med.* 2009;June. doi:10.1136/bjism.2009.057968.

84. Aichroth P. Osteochondritis dissecans of the knee: a clinical survey. *J Bone Joint Surg.* 1971;53:440-447.
85. Rowley D. *The Musculoskeletal System.* New York, NY: Chapman & Hall Medical; 1997;246.
86. Fleming B, et al. Ligament injury, reconstruction, and osteoarthritis. *Current Opinion in Orthopaedics.* 2005;16(5):354-362.
87. Hartnett N, et al. Delay in diagnosis of anterior cruciate ligament injury in sport. *N Z Med J.* 2001 Jan 26;114(1124):11-3.
88. Feretti A. Osteoarthritis of the knee after ACL reconstruction. *Int Orthop.* 1991;15:367-371.
89. Oiestad B, et al. Knee osteoarthritis after anterior cruciate ligament injury. *The American Journal of Sports Medicine.* 2009;37(7):1434-43.
90. Nelson F, et al. Early post-traumatic osteoarthritis like changes in human articular cartilage following rupture of the anterior cruciate ligament. *Osteoarthritis and Cartilage/OARS, Osteoarthritis Research Society.* 2006;14(2):114-119.
91. Iozzo R. Matrix proteoglycans: from molecular design to cellular function. *Annu. Rev. Biochem.* 1998;67:609-652.
92. Sampson S, et al. Injection of platelet-rich plasma in patients with primary and secondary knee osteoarthritis: a pilot study. *Am J Phys Med Rehabil.* 2010;89:961-969.
93. Ventura A, et al. Use of growth factors in ACL surgery-preliminary study. *Journal of Orthopaedic Traumatology.* 2008;6:76-79.
94. Kajikawa Y, et al. Platelet-rich plasma enhances the initial mobilization of circulation-derived cells for tendon healing. *J cell Physiol.* 2008;215(3):837-45.
95. Lyras D, et al. Immunohistochemical study of angiogenesis after local administration of platelet rich plasma in a patellar tendon defect. *International Orthopaedics.* 2010;34(1):143-148.
96. Kon E. et al. Platelet rich plasma: new clinical application. A pilot study for treatment of jumper's knee. *Injury, Int. J. Care Injured.* 2009;40:598-603.
97. Yadav H, et al. Rotator cuff tears: pathology and repair. *Knee Surg Sports Traumatol Arthrosc.* 2009;17(4):409-21.
98. Carpenter J, et al. Rotator cuff defect healing: a biomechanical and histologic analysis in animal model. *J Shoulder Elbow Surg.* 1998;7(6):599-605.
99. Gamradt S, et al. PRP as a treatment alternative for symptomatic rotator cuff tendinopathy for patients failing conservative treatments. *Techniques in Orthopaedics.* 2007;22(1):26-33.
100. United States Bone and Joint Decade: *The burden of musculoskeletal diseases in the United States.* Rosemont IL: American Academy of Orthopaedic Surgeons; 2008.
101. Centers for Disease Control and Prevention. Arthritis prevalence and activity limitations, United States, 1990. *MMWR Morbid Mortal Wkly Rep.* 1994;43:433-8.
102. American Academy of Orthopaedic Surgeons. (2009, April). Half of all musculoskeletal injuries occur in home. Retrieved October 4 2011 from <http://www.aaos.org>.